

//  
//

( )

\*

*Spearman*

*McNemar*

%

% /

% /

% /

/

(*P* < /)

(*CVMS*)

(*HWMS*)

.( )

( )

( )

( )

( )

( )

( )

.( )

open bite

cl III

cl II

cross bite

.( )

Greulich ( )

Bjork ( ) Pyle

( ) TW2 ( )

contrast

( )

distortion

sharpness

( )

HWMS

Grave & Brown

( )

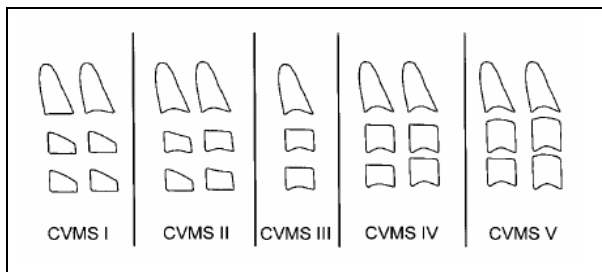
( )

( ) Baccetti

CVMS

( )

( )



( Diagnostic study)

( )

( )



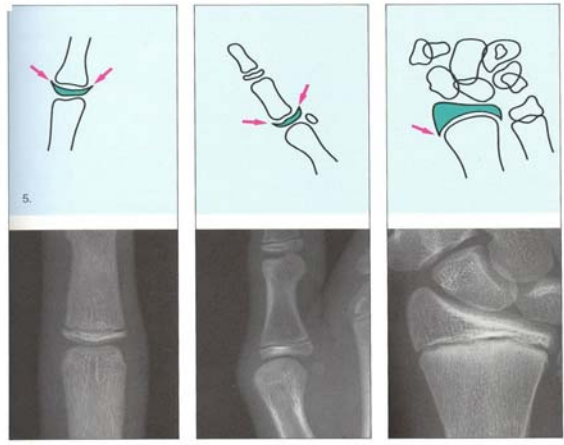
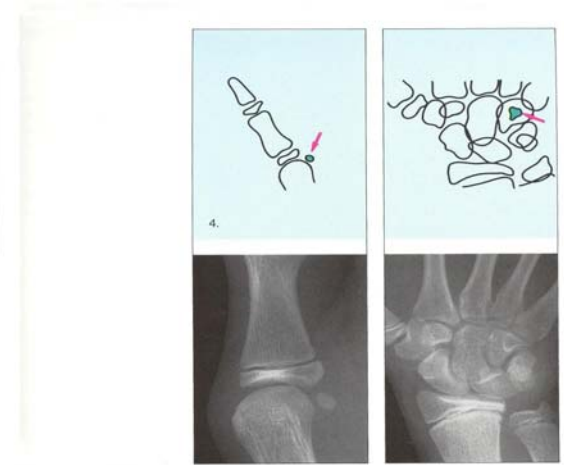
DP<sub>3</sub> (

PP<sub>3u</sub> (

MP<sub>3u</sub> (

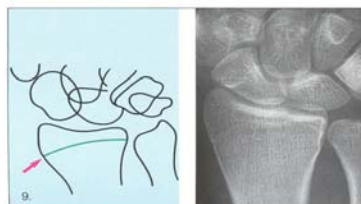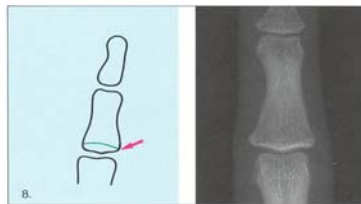
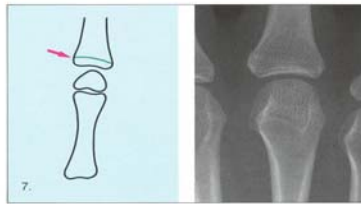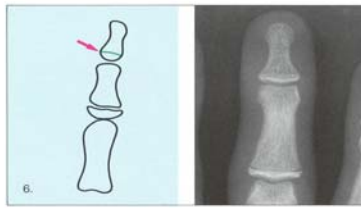
R<sub>u</sub> (

( )



McNemar

Spearman



: (

S (

Metacarpophalangeal

H (

Hamatum

: (

MP<sub>3 cap</sub> (

PP<sub>1cap</sub> (

R<sub>cap</sub> (

( )

				( )				
				(% / )				
% / % %		CVMS		( )			(% / )	
( / )		% % /		(% )		(% )		
	HWMS	CVMS		.	/ ± /	± /		
CVMS	/							
HWMS	CVMS		HWMS					
Ordinal				% /				
				(Positive Predictive Value)			%	
				Negative Predictive )			% /	
	HWMS	CVMS		CVMS			% / (Value	
				CVMS			% /	
Fernandez				% /				
( )		( )					%	
Fishman								
				( )	(+ )			
( )	kucukkeles							
( )				(% / )	(% / )	(% / )	(+ )	
				(% / )	(% / )	(% / )	( )	
Fishman				(% )	(% / )	(% / )		
	"						McNemar	
Chang	"							
( )		( )		(r)			(P< / )	
	%			(r <sup>2</sup> )	/	HWMS	CVMS	
				CVMS	%		/	
	"						HWMS	

Mito "

%

( )

TW2

Paolo Gandini

( )

"

"

)

( )

Caltabiano

%

(

late effect Stochastic

%

)

Late Adolescent ,

Average Adolescent , Early Adolescent

C

.

(Maturation Level)

%

## **REFERENCES**

---

1. Mir C F, Burgess C A. Correlation of skeletal maturation stages determined by cervical vertebrae and hand-wrist evaluations. *Angle Orthod* 2006; 76: 1-5.
2. Rakosi T, Jonas I, Graber TM. *Color Atlas of Dental Medicine: Orthodontic Diagnosis* Stuttgart, Germany: Georg Thieme Verlag pub. 1989.
3. Taushe E, Luck O, Haizer W. Prevalence of malocclusion in the early mixed dentition and Orthodontic treatment need. *Eur J Orthod* 2004; 26: 237-44.

- 
4. Hagg U, Taranger J. Menarche and voice change as indicators of the pubertal growth spurt. *Acta Odontologica Scandinavica* 1980; 38: 179-86.
  5. Fishman LS. Chronological versus skeletal age, an evaluation of craniofacial growth. *Angle Orthod* 1982; 49: 181-9.
  6. Hagg U, Matsson L. Dental maturity as an indicator of chronological age: the accuracy and precision of three methods. *Eur J Orthod* 1985; 7: 25-35.
  7. Tanner JM, Whitehouse RH, Marshal WA, Healy MJR, Goldstein H. Assessment of skeletal maturity and prediction of adult height: TW2 method. Academic Press. 1975.
  8. Green LJ. The interrelationships among height, weight and chronological, dental and skeletal ages. *Angle Orthod* 1961; 31: 189-93.
  9. Grave KC, Brown T. Skeletal ossification and the adolescent growth spurt. *Am J Orthod* 1976; 69: 611-9.
  10. Greulich W, Pyle S. *Radiographic Atlas of Skeletal Development of Hand and Wrist*. Stanford, CA: Stanford University Press. 1959.
  12. Gandini P, Mancini M, Andreani F. A comparison of hand-wrist bone and cervical vertebral analyses in measuring skeletal maturation. *Angle Ortod* 2005; 76: 984-9.
  13. Nanda SK. Circum pubertal growth spurt related to vertical dysplasia. *Angle Orthod* 1990;59:113-22.
  14. San Román P, Palma JC, Oteo MD, Nevado E. Skeletal maturation determined by cervical vertebrae development. *Eur J Orthod* 2002; 24: 303-311
  15. Lamparski DG. Skeletal age assessment utilizing cervical vertebrae [dissertation]. Pittsburgh: University of Pittsburgh, 1972.
  16. Hassel B, Farman AG. Skeletal maturation evaluation using cervical vertebrae. *Am J Orthod Dentfacial Orthop* 1995; 107: 58-66.
  17. Baccetti T. An improved version of the cervical vertebral maturation (CVM) method for the assessment of mandibular growth. *Angle Orthod* 2002; 72: 316-23.
  18. Grave K C, Brown T. Skeletal ossification and the adolescent growth spurt. *Am J Orthod* 1976; 69: 611-9.
  19. Rakosi T. *An atlas and manual of cephalometric radiography*. London: Wolfe Medical Publications. 1982; P: 8.
  20. Garcia-Fernandez , Torre H, Flores L, Rea J. The cervical vertebrae as maturational indicators. *J Clin Orthod* 1998; 32: 221-5.
  21. Kucukkeles N, Acar A, Biren S, Arun T. Comparisons between cervical vertebrae and Hand-wrist maturation for the assessment of skeletal maturity. *J Clin Pediatr Dent* 1999; 24: 47-52.
  22. Chang HP, Liao CH, Yang YH, Chang HF, Chen KC. Correlation of cervical vertebrae maturation with hand-wrist maturation in children. *Kaohsiung J Med Sci* 2001; 17: 29-35.
  23. Mito T, Sato K, Mitani H. Cervical vertebral bone age in girls. *Am J Dentofacial Orthop* 2002; 122: 380-485.

- 
24. Caltabiano M, Leonardi R, Zaborra G. Evaluation of cervical vertebrae for determination of skeletal age. Riv Ital Odontoiatr Infant 1990;1:15-20.