

//
//
//

()

PCNA ki – 67

*

R.E.E

Squamous cell carcinoma Mucoepidermoid carcinoma Ameloblastoma

PCNA ki- 67 .

PCNA Ki-67

IHC PCNA ki-67

streptavidin- avidin biotin

%

Ki-67

%

%

%

PCNA

PCNA , ki-67

PCNA ki – 67

() .

REE

REE

CEJ

()

(Cervicoenamel Junction)

PCNA ki- 67 .()

()

PCNA Edematsu
ki-67

()

Ki-67 PCNA Multi Potential

Ki-67 SCC (Mucoepidermoid Carcinoma) MEC
(Squamous Cell Carcinoma)
()

DNA

PCNA

DNA- Polypeptidase
() G1/S Peak . Konstantinos .
G2 ki-67

()
PCNA Matulova

Immunohistochemistry

() ki-67 Piatelli

(Clone Sigma 1: 100 PC 10) PCNA

(Clone MIBI 1: 100) anti- ki-67 Ki-67

: • Ki-67
 (shun)
 (++) (+)
 (+) (++)
 X4
 (++) X10 (++)
 () (+) X40

% %
 % %

IHC
Avidin- Biotin

H2O2 % /

Antigen retrieval
(700 watt) Microwave

Ki-67 (%)
()

(P < /)

Ki-67

USA, DAKO, Ki-67 PCNA clone :Pc10)
/ (clone:MIB-1

ki-67 /	
(%)	(%)
()	()
()	()

Biotinlated- antimouse immunoglobulin
 (Denmark, DAKO , Ko673)
 (D.A.B) diaminobenzidine tetrahydrochloride

(%) PCNA
 (%)
 ()

Meyer's hematoxilin counterstain
 mount counter stain

(P < /)

anti PCNA

(++) (+) (++)
 (+++)
 .(P< /)

PCNA

(++) (+)
 (+++) (++) (+)

.(P< /)

ki- 67

(+) (++) (+)
 (++) (++)
 .(P< /)

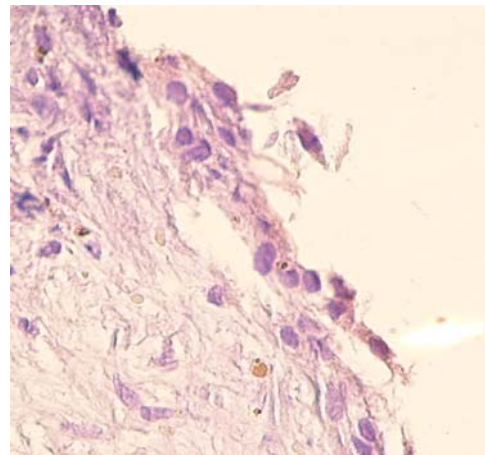
PCNA Ki-67

Edematsu
 Edematsu

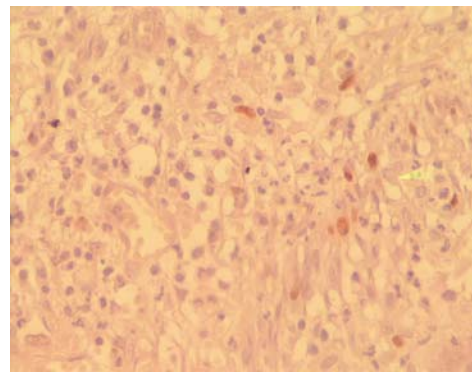
() Edematsu
 .() Matulva
 () Tripi
 PCNA ki- 67

PCNA

(%)	(%)	PCNA /
()	()	
()	()	



PCNA



PCNA

() PCNA () ki- 67
 () Edematsu () ki- 67
 (++) (+)
 (++) (++)
 .(P< /)

case-control

Ki-67 PCNA

cohort

PCNA Ki-67

()

Sharshita

cystic precystic

(EGF)

REFERENCES

1. Ten Cate AR. Oral Histology: Development, structure and function RK 280. T96, 6th ed. St Louis: The CV Mosby. 2003; PP: 1-6.
2. Neville B, Damm D, Allen M, Bougot J. Oral and Maxillofacial Pathology. 2nd ed. WB Saunders. 2002; PP: 590-5.
3. Regezi JA, Sciubba JJ, Jordan R. Clinical pathologic correlation. 4th ed. WB Saunders. 2003; PP: 246-8.
4. Edematsu M, Kumamoto H, Ooya K, Echigo S. Apoptosis - related factor in the epithelial components of dental follicle and dentigerous cysts associated with impacted third molar of mandible. Am J Oral Surg Oral Pathol Endod 2005; 99: 17-23.
5. Piatelli AD, Lezzi G, Fioroni MA, Santinelli AL, Fubini MM, Santinelli AF, et al. Ki- 67 expression in dentigerous cyst, unicystic ameloblastoma and ameloblastoma arising in dentigerous cyst. Am J Endodon 2002; 128: 56-62.
6. Konstantinos J, Karantza E, Karantza AN. Immunohistochemical study of bel-2 protein, Ki-67 and P53 protein in epithelial of glandular odontogenic cyst and dentigerous cyst. Am J Oral Pathol Med 2000; 29: 139- 44.
7. Matulova P, Witter K, Misek J. Proliferating cell nuclear antigen (PCNA) expression in tooth primordial in the fide vole (microtus agrestis Rodentia). Connect Tissue Res 2002; 43: 138-42.

8. Trippi TR, Bonaccorso A, Rapisarda F, Bartoloni G. Proliferative activity in periapical lesion. *Aus J Endod* 2003; 29: 31-3.
9. Sharshita P, Yamada K, Higa S, Mori M. Epidermal growth factor receptor in odontogenic cyst and tumors. *Am J Oral Pathol Med* 1992; 21: 314-7.