

//
//

()

pulse tissue Doppler

*

pulse tissue Doppler (PTD)

PTD Doppler M Mode 2D

PTD

(Early peak velocity/ Late peak velocity) E/A PTD

DT (Deceleration time) (P< /) RT (relaxation time) (P< /)

E/A (P< /) late peak velocity(Am) (P< /)

(P< / r= /) E/A

Longitudinal

E/A RT

PTD

pulse tissue Doppler :

Congestive Heart Failure ()

hasannamazi@yahoo.com :

[(BP \geq /)] ()
 [() after load
 : remodeling geometry
 Valvular regurgitation ()
 Valvular heart disease
 ECC ()
 wall motion abnormality pulse Doppler
 (pulmonary hypertension COPD) ()
 Congestive Heart Failure tissue Doppler Imaging
 () direction
 Doppler pulse tissue Doppler
 ()
 PTD ()
 HR ()
 Longitudinal
 Doppler M-mode 2D ()
 pulse tissue Doppler
 Vingmed system five ultrasound system ()
 tissue Doppler Longitudinal
 3.5 MHS
 Septal wall M-Mode pulse tissue Doppler
 left ventricular post wall right ventricular ant wall
 (Dimension Left Ventricular End Diastolic) LVEDD
 (LV End Systolic Dimension) LVESD
 left ventricular fractional shortening
 TAPSE

[S (Tricuspid Annular Plane Systolic Excursion)
 Em peak(m/s)
 Am peak(m/s) [myocardial early peak velocity] 2D TAPSE ()
 [myocardial late peak velocity] apical four chamber
 [deceleration time] DTm(ms) Em/Am
 relaxation time] RTm(ms) RV
 [Em Sm
 mean ± SD EF=3.2×TAPSE(mm)
 SPSS 11.5 Kaul () RV
 t Chi-square pulse Doppler
 P< / sample volume apical four chamber
 Tip
 A-peak velocity E-peak velocity
 (Isovolumic relaxation time) IVRT E/A
 (Diastolic filling period) DFP
 DFP E/A Apeak Epeak
 (heart rate) pulse tissue Doppler ()
 BMI 3.5 MHS
 sample volume . apical four chamber
 (P< /) lateral mitral annulus
 2D M Mode LV
) RV ant wall thickness sample volume
 (P< / / ± / / ± / RV lateral tricuspid annulus
) LV post wall thickness pulse tissue Doppler
 (P< / / ± / / ± / Sm
 / ± /) LVEDD Am Em
 (P< / ± Sm peak (m/s) :
 PCT (mm) [myocardial systolic peak]
 left ventricular- LVESD QRS precontraction time]
 TAPSE fractional shortening contraction time] CT(mm) [Sm

(P< /)

PTD

RV

:

(.)

Em

Em

Myslinski

mild to mod

(P< / r= /)

Em/Am

Em/Am

peak velocity

(P< / r= /)

RV filling

TE/TA

()

(.)

LV filling

RTm

RTm

(P< / r= /)

PTD

DTm Am

Cicala

PTD

Em/Am

(P< /) DTm (P< /) RTm (P< /)

(P< /) Em peak

()

PTD

M Murat Tumuklu

PTD

lat tricuspid annulus

E/A (P< /) peak A (P< /) peak E

mid RV free wall PTD (P< /)

E/A (P< /) A (P< /) E

(P< /) peak (P< /)

Strain Imaging PTD

Doppler

pulse Doppler

Chakko

(.)

DT (P< /)

RV peak velocity

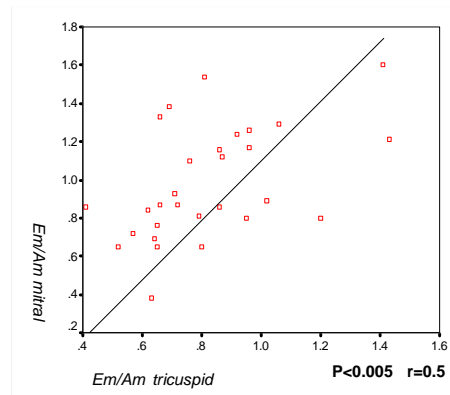
E/A

(P< /)

(right ventricular wall impairment)

SV

peak filling rate



Em/Am

overload Longitudinal

Longitudinal

PTD

Em/Am ventricular relaxation Em :

RTm DTm atrial activity Am

Em/Am < (P< /)

RTm (P< /)

isometric relaxation

(P< /) DTm (P< /)

TAPSE

Ventricular interaction PTD

pulse tissue Doppler filling filling

Doppler RTm Em/Am Em peak

DTm Am peak

video tape functional intraction Em/Am

passive

REFERENCES

1. John D, Otto C, Hess M. Assessment of normal and abnormal cardiac function. In: Zipes DP, Bonow R, Braunwald E, editors. Heart disease, 7th ed. Philadelphia: Elsevier. 2005; PP: 497-501.
2. Dougherty AH, Naccarelli GV, Gray E, Hicks CH, Goldstein RA. Congestive heart failure with normal systolic function. Am J Cardio 1984; 54: 778-82.
3. O' Conner CM, Gattis WA, Shawl L, Cuffe MS, Califf RM. Clinical characteristics and long-term outcome of patients with heart failure and preserved systolic function .Am J Cardiol 2000; 86: 863-7.

-
4. Galderisi M, petrocelli A, Alfieri A, Garofalo M, de Divitis O. Impact of ambulatory blood pressure on left ventricular diastolic function. *Am J Caradiol* 1996; 77: 597-601.
 5. Cicala S, Galderisi M, Caso P, Petrocelli A, D'Errico A, de Divitiis O, et al. Right ventricular diastolic dysfunction in arterial systemic hypertension analysis by pulsed tissue Doppler. *Eur J Echocardiogr* 2002; 3(2): 135-42
 6. Chakko S, de Marchena E, Kessler KM, Materson BJ, Myerburg RJ. Right ventricular diastolic function in systemic hypertension. *Am J Cardiol* 1990; 65:c1117-20.
 7. Myśliński W, Mosiewicz J, Ryczak E, Barud W, Biłan A, Palusiński R, et al. Right ventricular diastolic function in systemic hypertension. *J Human Hypertension* 1998; 12 :149-155.
 8. Caso P, Galderisi M, Cioppa C, Severino S, De Simone L, Izzo A, et al. Regional diastolic function in normotensive versus hypertensive subjects: comparison using Doppler myocardial imaging. *G Ital Cardiol* 1997;27(1): 901-7.
 9. Poulsen SH, Andersen NH, Ivarsen PI, Mogensen CE, Egeblad H. Doppler tissue imaging reveals systolic dysfunction in patients with hypertension and apparent "isolated" diastolic dysfunction. *J Am Soc Echocardiogr.* 2003; 16(7): 724-31.
 10. Garcia-Fernandez MA, Azevedo J, Moreno M, Bermejo J, Moreno R. Regional Left Ventricular Diastolic Dysfunction Evaluated by Pulsed-Tissue Doppler Echocardiography. *Echocardiography* 1999; 16: 491-500.
 11. L eggio M, Sgorbini L, Pugliese M, Mazza A, Bendini MG, Fera MS, et al. Systo-diastolic ventricular function in patients with hypertension: an echocardiographic tissue doppler imaging evaluation study. *Int J Cardiovasc Imaging* 2007; 23(2):177-84.
 12. Tumuklu MM, Erkorkmaz U, Ocal A. The impact of hypertension and hypertension-related left ventricle hypertrophy on right ventricle function. *Echocardiography.* 2007; 24(4): 374-84.
 13. Kaul S, Tei C, Hopkins JM, Shah PM. Assessment of right ventricular function using two dimensional echo. *Am Heart J* 1984; 107: 526-31.