

( )

//  
//

**(OKC)**

\*

(OKC)

:  
OKC .

OKC

OKC

:

OKC

( )

OKC

OKC

:

OKC

:

(IHC)

:

OKC

(OKC)

OKC

.( )

.( )

Hormia

OKC

(.)

OKC

OKC

Incisional

(.)

(.)

Morgan

OKC

OKC

OKC

OKC

Mathew

OKC

OKC

OKC

GAO (.)

(.)

OKC

OKC

OKC

(.)

(.)

OKC

(.)

Meredith

Fine Needle Aspiration Biopsy

(FNAB)

OKC

OKC

OKC

OKC

(.)

(mono clonal anti -

DAB  
Mouse)

( )

(Overnight)

Silon coated  
Oven

)

(

)

(Xylene)

(

:

%

PH= % / )

(

( )	( )
( )	(+)
( )	(++)
( ) ( )	(+++)

PH=6

)

(

(Room temperature)

PBS

Non-serum protein

OKC

% / OKC

% /

% /

(Anti

PBS

human cytokeratin)

%

%

%

( )

(% ) OKC

(% )

(P < / )

(% )

(% )

(% ) OKC

(P < / )

% OKC %

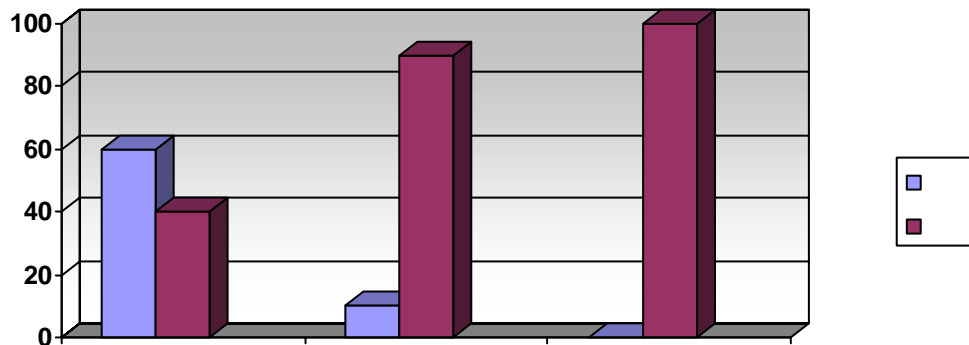
% OKC

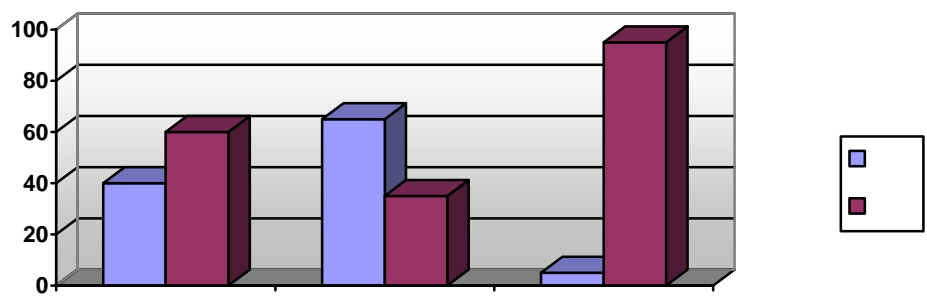
%

(% / )	(% / )	(N=19)
(% / )	(% / )	(N=12)
(% / )	(% / )	(N=16)
(% / )	(% / )	(N=47)

Mann – Whitney

OKC





-

( )

OKC

( )

( )

( )

OKC

Morgan

OKC

OKC

% OKC %

( )

% OKC %

Mathew

OKC

OKC

( )

OKC

## OKC

**REFERENCES**

1. Neville D, Allen B. Oral and Maxillofacial Pathology . 2<sup>nd</sup> Ed. Wb Saunders 2002.
3. Mervyne S. The aggressive nature of the odontogenic keratocyst: is it a benign cystic neoplasm? Part 1: Clinical and early experimental evidence of aggressive behaviour. J Oral Oncol 2002;38:219-26.
4. Meredith A, William CF, Maria T, Leonard BK. Differentiation of odontogenic keratocyst from non keratinizing cysts by use of FNA (Fine-Nedle Aspiration) Biopsy and cytokeratin 10 staining . J Oral Maxillofac Surg 2000;58:935-40.
5. Ben Z. Hean and Neck surgical pathology. Williams and Wikins and wikins 2000. pp:204-20.
6. Mervyn S. The aggressive nature of the odontogenic keratosyst : is it a benign cystic neoplasm ? part 2 : proliferation and genetic studies. J Oral Oncol 2002;38:407-15.
7. John GM, Ben ZP, Samir SS, Michael J. Cytokeratin expression in the odontogenic keratocyst. J Oral Maxillofac Surg 2000;58:862-5.
8. Home M. Epression of cytokeratin in odontogenic jaw cysts: Monoclonal antibodies reveal distinct variation between the different cyst types. J Oral Pathology 1987;16:338-46.
9. Morgan PR, Shirlow PJ, Johnson NW. Potential application of antikeratin antibodies in oral diagnosis . J Oral Pathol 1987;16:212-22.
10. Gao Z, Mackenzie IC. Cytokeratin expression of the odontogenic epithelia in dental follicles and developmental cysts. J Oral Med 1989;18(2):63-7.
11. McDonald AW, Fletcher A. Expression of cytokertatin in the epithelium of dentigerous cysts and odontogenic keratocysts. And aid to diagnosis . J Clin Pathol 1989;42:736-9
12. Mervyn S: The aggressive nature of the odontogenic keratosyst : is it a benign cystic neoplasm? Part 3: Immunocytochemistry of cytokeratis and other epithelial cell markers. J Oral Oncol 2002;(38):407-15.

- 
13. Morgan PR, Shirlow PJ, Jhonson NM, Lerigh IA, Lane EB. Potential applications of antikeratin antibodies in oral diagnosis. *J Oral Pathol* 1987;16:212-22.
  14. Mathews JB, Moson GI, Browne RM. Epithelial cell markers and proliferating cells in odontogenic jaw cysts. *J Pathol* 1988;156:283-90.