

//
//
//

()

*

/ ± /

()

% / %
% / %

. % / % /

()

%

()

()

)

()

.() (

() ()

(.)

(.)

(ε) Induction

())

(

(.)

)

MRI CA

GnRH Agonist

(

CT scan

)

()

()

(

(Fassa ovarian)

()

()

(% .)

Kiel

SPSS

% % %
. % %

.() % / % /

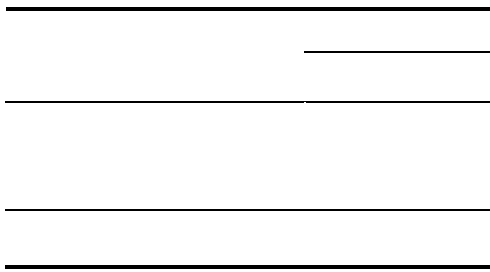
P= / /

/ ± /

McNemar

(%) (%) (%)
(%) (% /)
)

.(P < /)



(

% %

%

% % %

% %

% % %

. %

% %

% %

% %

%

.()

.()

.()

()

% /

.()

Balash

-

(%)

()

()

%

.()

(%)

%

()

% /

% /

% /

.()

% /

()

% /

.()

% /

.()

% ()

%

kiel

.()

(%)

Accuracy rate

REFERENCES

1. Speroff L, Fritz MA. Clinical Gynecologic Endocrinology and Infertility. 7th ed. Philadelphia: Lippincott Williams & Wilkins. 2005; P: 1103-25.
2. Berek JS. Novak's Gynecology. 13th ed. Philadelphia: Lippincott Williams & Wilkins. 2002; P: 931-72.
3. Mounsey AL, Wilgus A, Slawson DC. Diagnosis and management of endometriosis. Am Fam Physician 2006; 74(4): 594-602.
4. Wellbery C. Diagnosis and treatment of endometriosis. Am Fam Physician 1999; 60(6):1753-68.
5. Walter J, Hentz JG, Magtibay PM, Cornella JL. Correlation between histological and visual findings at laparoscopy. Am J Obstet Gynecol 2001; 184(7): 1407-13.
6. Mettler L, Schollmeyer T, Lehmann-Willenbrock E, Schuppler U, Schmutzler A, Shukla D, et al. Accuracy of laparoscopic diagnosis of endometriosis. JSLS 2003; 7(1): 15-8.
7. Marchino GL, Gennarelli G, Enria R, Bongioanni F, Lipari G, Massobrio M. Diagnosis of pelvic endometriosis with use of macroscopic versus histological findings. Fertile Steril 2005; 84(1): 12- 5
8. Schollmeyer T, Pandit K, Schmutzler A, Mettler L. Correlation of endoscopic interpretation of endometriosis with histological verification. Clin Exp Obstet Gynecol 2004; 31(2): 107- 9
9. Spaczynski RZ, Duleba AI. Diagnosis of endometriosis. Semin Reprod Med 2003; 21(2): 193- 208.
10. Leng JH, Lang JH, Zhao XY, Li HJ, Guo LN, Cui QC. Visual and histologic analysis of laparoscopic diagnosis of endometriosis. Zhonghua Fu Chan Ke Za Zhi. 2006; 41(2):111-3.
11. Balasch J, Creus M, Fabregues F, Carmona F, Ordi J, Martinez-Roman S, et al. Visible and non-visible endometriosis at laparoscopy in fertile and infertile women and in patients with chronic pelvic pain: a prospective study. Hum Reprod. 1996; 11(2): 387-91.