

//  
//

( )

\*

---

*(Temporal Myoplasty)*

/ ±  
/ ±  
% (static)  
(dynamic) % % % %  
% % %

**static**

---

( )

( )

( )

gold standard

( )

( )

( )

( )

labbe

caen

(Release)

( )

(Coronoid process)

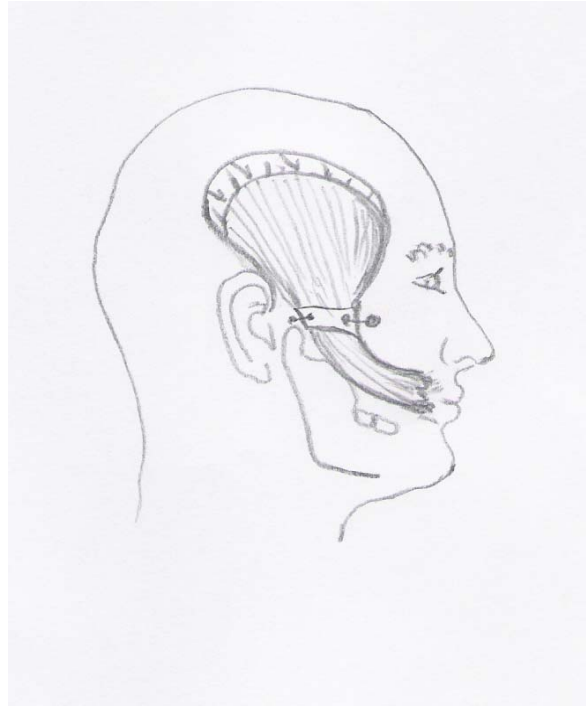( )

(alopecia)

( )

(dissection)

- mm



( )

( )

cm

(temporal crest)

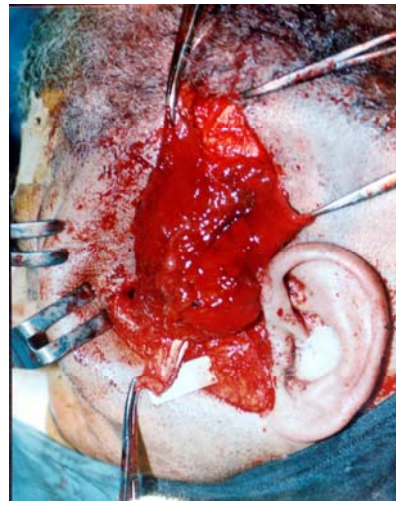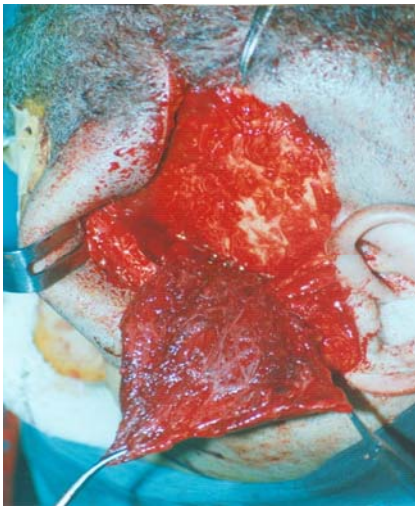
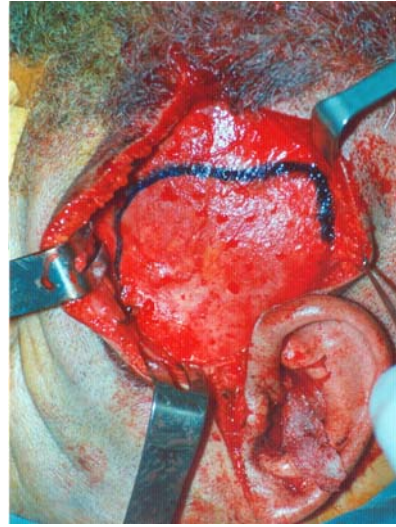
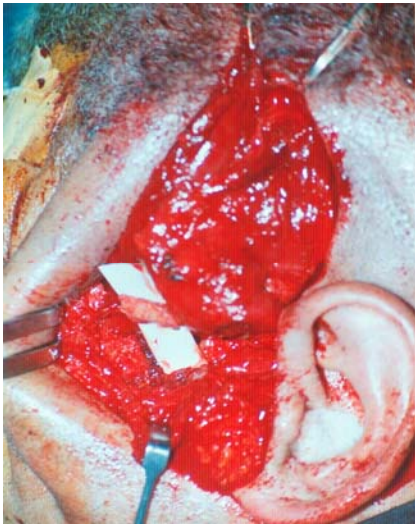
(fossa temporal)

(coronal)

(infra temporal crest)

( )

cm



(Nasolabial crease)

(masseter)

(commissure)

/

,

%

%

%

%

%

(dynamic)

%

%

%

/ ±

)

/ ± /

(

%

/ ± /

%

(static)

---

---

---

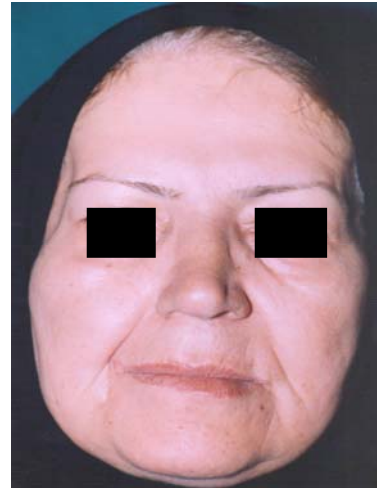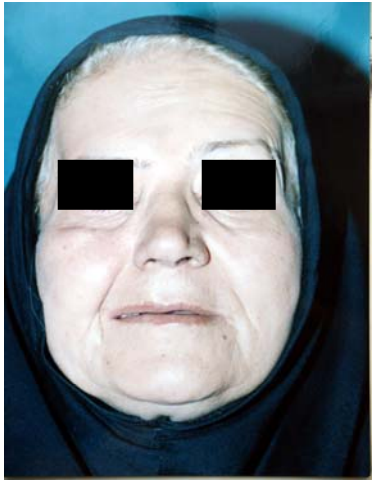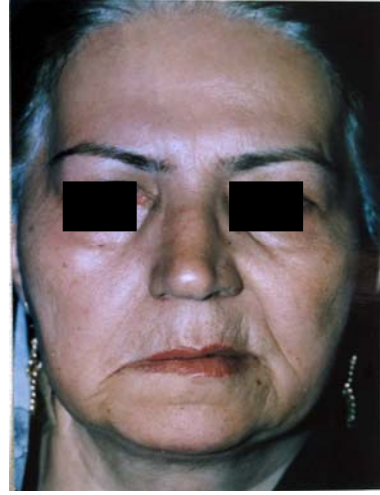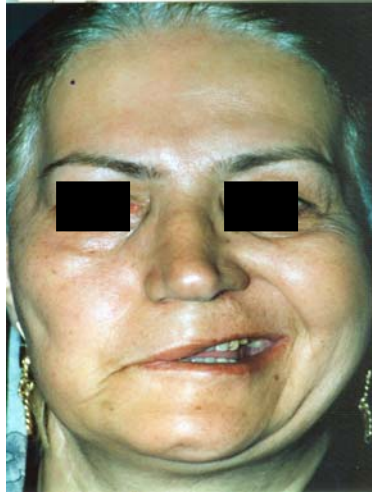---

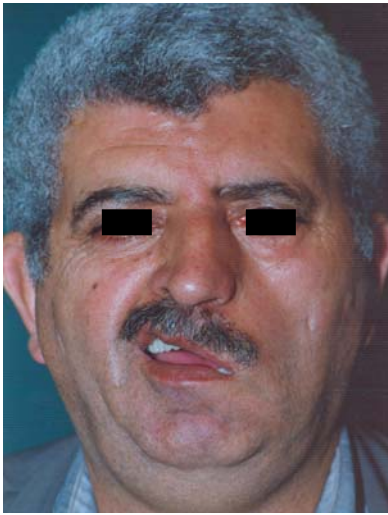---

|     |    |     |     |
|-----|----|-----|-----|
| *** | ** | *** | *** |
| **  | ** | *** | **  |
| *   | ** | *   | **  |
| *** | ** | *** | *** |
| *** | ** | *** | *** |
| **  | ** | **  | **  |

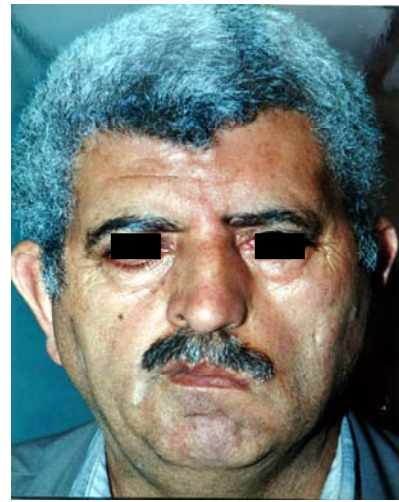\*\*\* \*\* \*

( ) (static) .( )  
( )  
( )

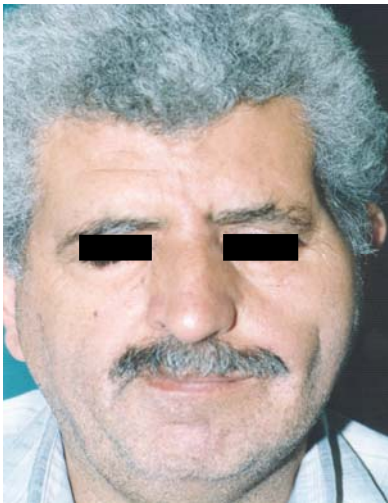



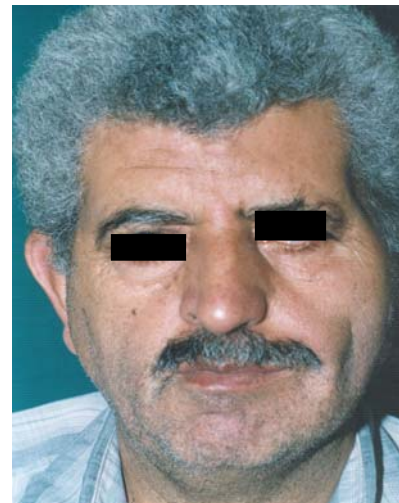:



:



:



:

(.)

( ) gold standard

(bulge)

( )

suspension

( )

" "

( )

( )

Masseter

( )

( )

( )

VII - V

( )

(interoral approach)

(commissure)

(occlusal plan)

(myoplasty masseter)

( )

Gillis

---

## REFERENCES

---

1. Zuker RM, Manktelow RT, Hussain G. In: Mathes SJ. Plastic surgery. 2<sup>nd</sup> ed. Vol 3. Philadelphia: Saunders. 2006 P:883-916.
2. Baker DC. Reconstruction of the Paralysed face. In: Grab and Smith plastic surgery. 5<sup>th</sup> ed. Philadelphia: Lippincott Raven. 1997; P:545-57.
3. Baker DC. Facial paralysis. In: Mc Carthy Plastic surgery. 1<sup>st</sup> ed. Philadelphia: W.B Saunders. 1990; P:2255-306.
4. Ueda K, Harii K, Asato H, Yamada A. Neurovascular free muscle transfer combined with cross-face nerve grafting for the treatment of facial paralysis in children. *Plast Reconstr Surg* 1998;101(7):1765-73.
5. May M, Drucker C. Temporalis muscle for facial reanimation. A 13-year experience with 224 procedures. *Arch Otolaryngol Head Neck Surg.* 1993;119(4):378-82; discussion 383-4.
6. Hu ZQ, Ogawa R, Aoki R, Gao JH, Hyakusoku H. Temporalis muscle-galea pedicled flap for reconstruction of longstanding facial paralysis. *J Nippon Med Sch.* 2005;72(2):105-12.
7. Labbé D, Huault M. Lengthening temporalis myoplasty and lip reanimation. *Plast Reconstr Surg.* 2000;105(4):1289-97; discussion 1298.
8. Ueda K, Akiyoshi K, Suzuki Y, Ohkouchi M, Hirose T, Asai E, et al. Combination of hypoglossal-facial nerve jump graft by end-to-side neurotomy and cross-face nerve graft for the treatment of facial paralysis. *J Reconstr Microsurg.* 2007;23(4):181-7.
9. Alam D. Rehabilitation of long-standing facial nerve paralysis with percutaneous suture-based slings. *Arch Facial Plast Surg.* 2007;9(3):205-9.
10. Garanhani MR, Cardoso JR, Capelli Ade M, Ribeiro MC. Physical therapy in peripheral facial paralysis: retrospective study. *Rev Bras Otorrinolaringol (Engl Ed).* 2007;73(1):106-9.