

//

()

//

*

:

()

Case- Series

:

CT

(0-4)

(% /)

:

%

%

(P< /)

%

%

:

CT Scan

:

()

()

()

()

:0 :

:I ()

mm :II .()

mm :III

:IV

o ()

%

Case-Series

(Confidence Interval=C.I)

Chi-square

Odd's ratio

Osteoinduction

(% /) (% /)

/

C Arm

(% /)

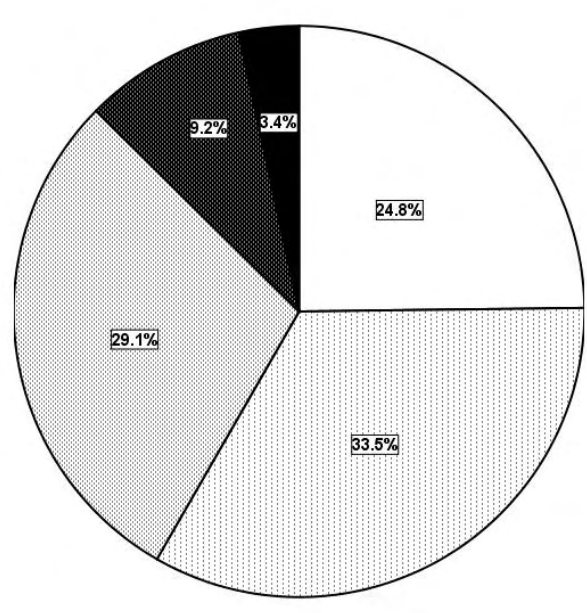
(% /)

/

T₁₂ T₁₁ T₁₀
L₁-S₁

(% /)
(% /)

/ /



grade0
grade1
grade2
grade3
grade4

/

(P< /)

/

/

(P< /)

/

(OR= /)

(P< /)

(OR=)

O.R		
	(%)	(%)
	(/)	(/)
P< /	(/)	(/)
	(/)	(/)
/	P< /	(/)
	(/)	(/)
	P< /	(/)
	(/)	(/)

()

% /

(%)

(%)

()

(% /)

(% /)

()

(% /)

(%)	(%)	(%)	(%)
()	()	()	()
()	()	()	()

/ ± /

/ ± /

/ ± /

/ ± /

()

AP

()

()

CT

%

%

%

()

REFERENCES

1. Youkilis AS, Quin DJ, McGillicuddy JE, Papadopoulos SM. Stereotactic Navigation for Placement of Pedicle Screws in the Thoracic Spine. *Neurosurgery* 2001; 48(4): 771-9.
2. Davne SH, Myers DL. Complications of lumbar spinal fusion with transpedicular instrumentation. *Spine* 1992; 17(Suppl6): S184-9.
3. West JL 3rd, Ogilvie JW, Bradford DS. Complications of the variable screw plate pedicle screw fixation. *Spine* 1991; 16: 576-9.
4. Lonstein JE, Denis F, Perra JH, Pinto MR, Smith MD, Winter RB. Complications associated with pedicle screws. *J Bone Joint Surg Am* 1999; 81: 1519-28.
5. Vanichkachorn JS, Vaccaro AR, Cohen MJ, Cotler JM. Potential large vessel injury during thoracolumbar pedicle screw removal. A case report. *Spine* 1997; 22: 110-3.
6. Bransford R, Bellabarba C, Thompson JH, Henley MB, Mirza SK, Chapman JR. The safety of fluoroscopically-assisted thoracic pedicle screw instrumentation for spine trauma. *J Trauma* 2006; 60(5): 1047-52.
7. Choma TJ, Denis F, Lonstein JE, Perra JH, Schwender JD, Garvey TA, et al. Stepwise methodology for plain radiographic assessment of pedicle screw placement: a comparison with computed tomography. *Spinal Disord Tech* 2006; 19(8): 547-53.
8. Liau KM, Yusof MI, Abdullah MS, Abdullah S, Yusof AH. Computed tomographic morphometry of thoracic pedicles: safety margin of transpedicular screw fixation in Malaysian Malay population. *Spine* 2006; 31(16): 545-50.
9. Fisher CG, Sahajpal V, Keynan O, Boyd M, Graeb D, Bailey C, et al. Accuracy and safety of pedicle screw fixation in thoracic spine trauma. *J Neurosurg Spine* 2006; 5(6): 520-6.

-
10. Karim A, Mukherjee D, Gonzalez-Cruz J, Ogden A, Smith D, Nanda A. Accuracy of pedicle screw placement for lumbar fusion using anatomic landmarks versus open laminectomy: a comparison of two surgical techniques in cadaveric specimens. *Neurosurgery* 2006;59 (Suppl 1): ONS 13-9.